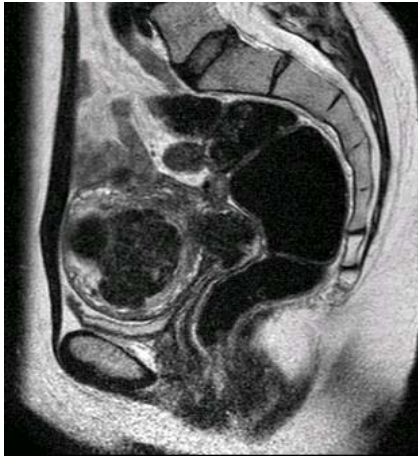
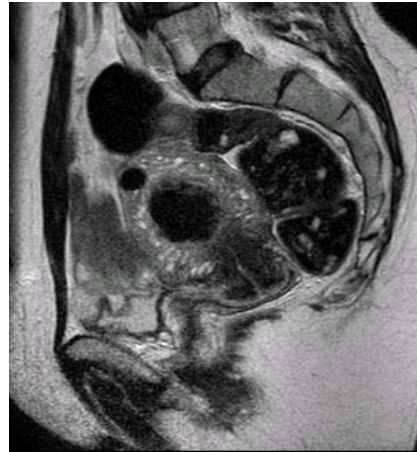
Atlas of Medical Pictures

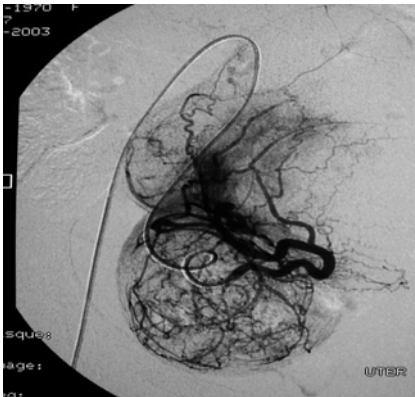
Uterine Artery Embolization for Fibroids



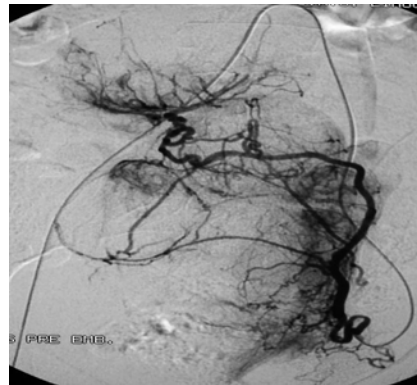Picture 1. Preembolization sagittal T₂-weighted midline magnetic resonance image, showing an enlarged uterus containing multiple fibroids.



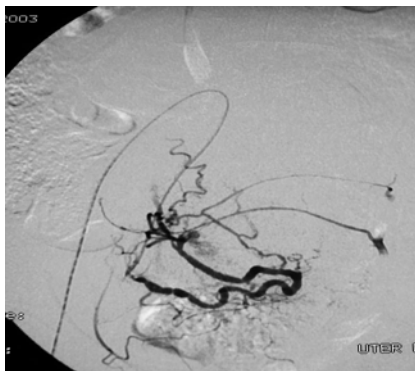
Picture 2. Sagittal T₂-weighted midline magnetic resonance image six months post-embolization, showing marked decrease in the size of the uterus and fibroids.



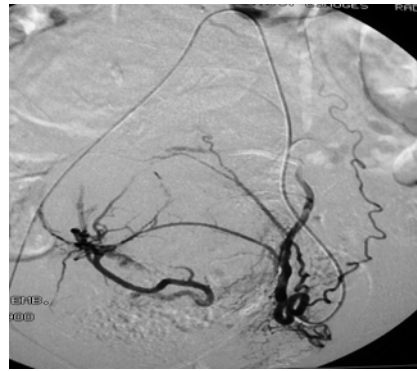
Picture 3. Digital subtraction arteriogram during embolization of the right artery showing the hypervascular arterial supply of multiple fibroids.



Picture 4. Digital subtraction arteriogram during embolization of left uterine artery showing the hypervascular arterial supply of multiple fibroids.



Picture 5. Digital subtraction arteriogram of the right uterine artery respectively after successful embolization.



Picture 6. Digital subtraction arteriogram of the left uterine artery respectively after successful embolization.

Pictures are a gift from: El-Dorry A, MD* and El-Serwi A, MSc**

*Professor and Head of the Unit, ** Specialist, Unit of Vascular and Interventional Radiology, Ain Shams University Hospitals.