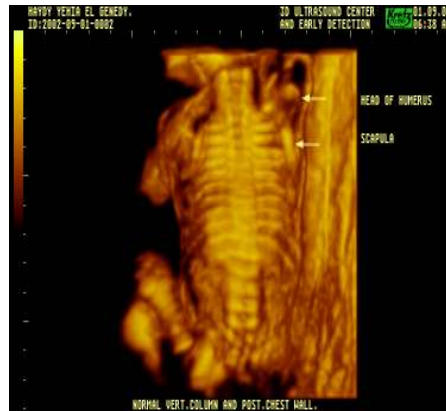


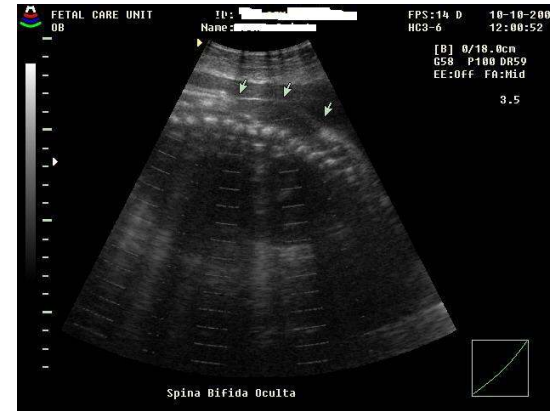Ultrasound In Neural Tube Defects

Aboul-Enein L, MSc and Mansour G, MD**

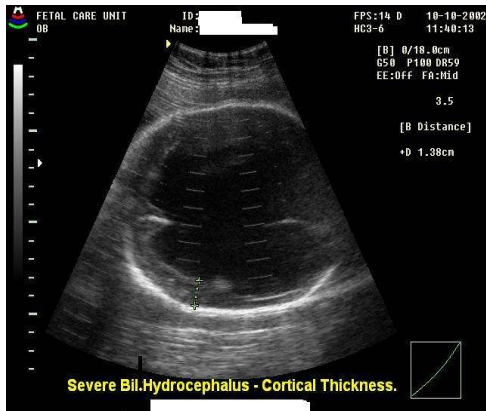
**Ob/Gyn Ultrasound Specialists, Department of Obstetrics and Gynecology, Ain Shams University*



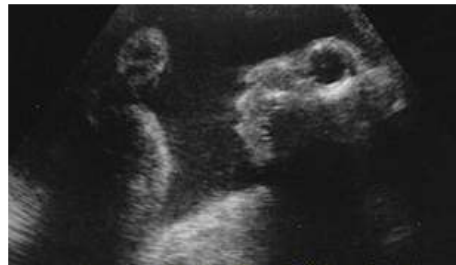3-D Picture of normal vertebral column



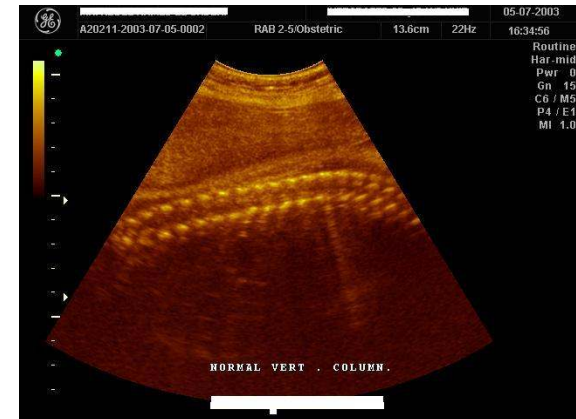
2-D Picture of spina bifida



2-D Picture of anencephaly



2-D Picture of severe hydrocephalus



2-D Picture of normal vertebral column